

Results of complex treatment of chronic rhinosinusitis in patients with community acquired pneumonia

Shahlo Xamidullayevna Bakiyeva

Republic of Uzbekistan, Tashkent Medical Academy, Department of Otorhinolaryngology, Uzbekistan

OPEN ACCESS

SUBMITTED 09 December 2024

ACCEPTED 11 January 2025

PUBLISHED 13 February 2025

VOLUME Vol.07 Issue02 2025

CITATION

Shahlo Xamidullayevna Bakiyeva. (2025). Results of complex treatment of chronic rhinosinusitis in patients with community acquired pneumonia. The American Journal of Medical Sciences and Pharmaceutical Research, 7(02), 37–40. <https://doi.org/10.37547/tajmspr/Volume07Issue02-05>

COPYRIGHT

© 2025 Original content from this work may be used under the terms of the creative commons attributes 4.0 License.

Abstract: As world statistics show, 60% of patients with chronic rhinosinusitis develop bronchopulmonary pathology. According to foreign authors, the number of patients with chronic rhinosinusitis increases annually by 1.5-2%, and today more than 2/3 of inpatients are affected by this pathology. Due to the anatomical, physiological and complementary characteristics of the upper and lower respiratory tracts, there is a tendency towards a protracted course of rhinosinusitis, which in turn leads to the spread of the infectious process to the lower respiratory tract. It should be noted that existing foci of infection in the upper respiratory tract spread to the lower respiratory tract through microaspiration after an acute respiratory illness, which is the cause of the development of chronic bronchitis, bronchial asthma, and in particular pneumonia. It should be noted that despite the efforts of a number of specialists in the treatment of pneumonia, in recent years there has been a significant increase in the incidence rate, as well as, unfortunately, an increase in mortality among people of various age groups.

Keywords: Chronic rhinosinusitis, upper and lower respiratory tract, community-acquired pneumonia.

Introduction: The results of medical statistics convincingly indicate an increase in the number of diseases of the nose, paranasal sinuses (PS) [1,2] and bronchopulmonary pathology [3]. The close anatomical and physiological connections between the upper and lower respiratory tracts are the reason that the increase in the incidence of rhinosinusitis has kept pace with the increase in the incidence of pulmonary diseases [4] and, in particular, community-acquired pneumonia (CAP).

The incidence of pneumonia in Europe and North America is 5–10 cases per 1 thousand population. The mortality rate from severe pneumonia reaches 10% and continues to rise [3;5]. Pneumonia most often occurs in children, the elderly and chronic diseases of the respiratory system. It is believed that in almost any acute respiratory viral infection, the paranasal sinuses are involved in the process to one degree or another [10]. Acute rhinosinusitis in 95% of cases is caused by viruses; 5-7 days after the onset of ARVI, a bacterial process develops [6,7]. Under the influence of the virus on the ciliated epithelium of the nasal cavity and paranasal sinuses, the epithelial cells lose their cilia, the epithelium becomes loose, and swelling of the mucous membrane develops. As a result of these processes, as well as the active release of pro-inflammatory mediators, an inflammatory reaction develops. The consequence of this is impaired aeration of the sinuses, inactivation of mucociliary clearance and accumulation of serous exudate in the lumen of the sinuses. Reducing the speed of mucociliary transport allows prolonging the time of contact of pathogenic bacteria with the mucous membrane and promotes bacterial infection [8,11].

The nasal cavity and paranasal sinuses are a highly organized structure, with a subtle and complex regulatory mechanism, which has many specific

functions. Such a morphofunctional system ensures the creation of the first barrier to the penetration of infection. A subtle functional connection between the nasal cavity and paranasal sinuses with other organs and systems, primarily with the bronchopulmonary system, is obvious.

METHODS

A total of 102 patients with community-acquired pneumonia who were hospitalized in the pulmonology department of the clinic of the Tashkent Medical Academy were examined. The age of patients ranged from 18 to 60 years (average 39.1 ± 1.14 years), the mean age of men was 34.1 ± 2.7 years, women 40.1 ± 2.9 years, respectively (Table 1).

Distribution by gender: men - 41 people (40.2%), women - 61 people (59.8%), men - 41 people (40.2%). Complaints and the history of the development of the disease were clarified in detail in all patients, and the general condition of the patients was examined. When collecting an anamnesis, the timing of the onset of the disease was specified, the timing of the occurrence of relapses, their relationship with infectious diseases of the upper respiratory system, and the presence of concomitant diseases of other organs were taken into account.

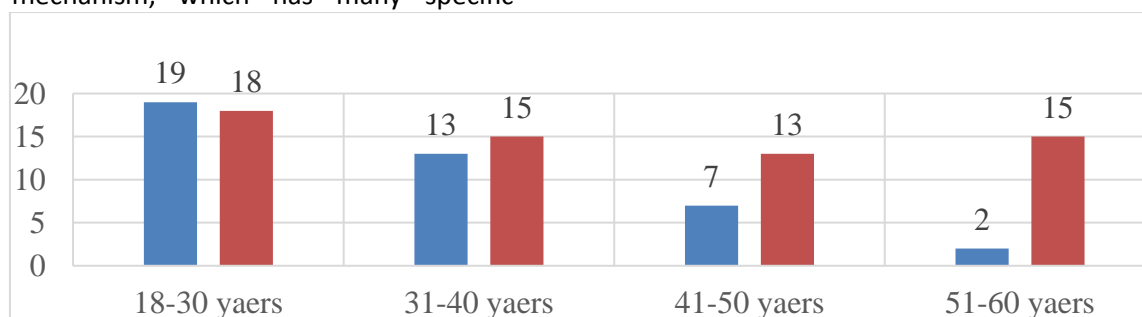


Table 1. Distribution of patients with CAP by sex (male/female) and age (n=102)

RESULT AND DISCUSSION

Of the total number of patients (102 patients), 62 patients underwent 3D radiography (MSCT) of the paranasal sinuses. X-ray changes in the paranasal sinuses showed an increase in the thickness of the mucous membrane of more than 6 mm. Obvious radiological changes were detected in 32 (51.6%) patients. In 2 patients, a subtotal and total decrease in

pneumatization of all paranasal sinuses was observed, i.e. a clear picture of pansinusitis, in 3 patients - right-sided and left-sided hemisinusitis, in 4 - right-sided maxillary ethmoiditis, in 7 patients - left-sided maxillary ethmoiditis, in 2 patients - bilateral maxillary ethmoiditis, in 10 patients signs of ethmoiditis and ethmoidosphenoiditis were revealed, respectively, in 4 patients - sphenoiditis.

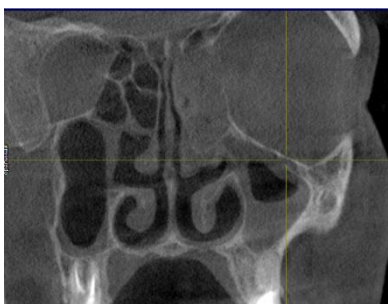

Figure 1. Patient D., 31 years old. 3D radiography of the paranasal sinuses. Identification of subtotal and total areas of blackouts in the left maxillary sinus and ethmoid cells

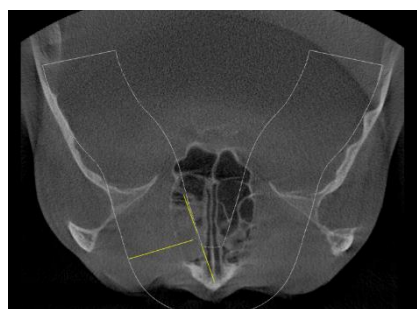


Figure 2. Patient G., 27 years old. 3D radiography of the paranasal sinuses subtotal and total areas of eclipse of the anterior and middle groups of cribriform cells.

As a result of the study, three groups of patients were formed: Group 1 - 32 patients diagnosed with clinically moderate/severe form of MS. The second group consisted of 30 patients diagnosed with "clinically mild MS." The third group included 40 patients without identified clinical signs of MS.

The first and second groups of patients received complex treatment: antibacterial therapy included drugs belonging to the group of cephalosporins (3-4 generations) and fluoroquinolones (2-3 generations), intranasal local glucocorticosteroids, acetylcysteine-containing drug 200 mg, 1 tablet 2 times a day for 10 days, antihistamines (Erius 5 mg, 1 tablet 1 time a day for 10 days), the nasal cavity was also sanitized with a

sterile isotonic solution of sea water. Since patients in group 3 did not have chronic inflammatory diseases of the nasal cavity and paranasal sinuses, patients in this group received only VBP treatment prescribed by a pulmonologist.

On the 30th day of the study, the clinical effectiveness of the complex treatment of CRS was 90.7%; three (9.3%) patients underwent endoscopic surgery on the sinuses due to the ineffectiveness of the treatment; during the operation it was revealed that the natural openings in the area of the osteomeotal complex were closed. Eight (25%) patients underwent elective septoplasty, and 9 (28.1%) patients underwent vasotomy (Table 1).

Table 1

Performed surgical and partially completed surgical measures in patients of group 1

Type of intervention	Number of operations performed (n)
Puncture of the maxillary sinus	7 (21,8%)
Functional endoscopic sinus surgery	3 (9,3%)
Septoplasty	8 (25%)
Vasotomy	9 (28,1%)

CONCLUSION

Complex use in the treatment of CRS in patients with CAP based on data from a microbiological study to

determine the type of microorganisms and their sensitivity to antibiotics, cephalosporin drugs of the III-IV generation and fluoroquinolones of the II-III generation (cefoperazone, levofloxacin), as well as

intranasal glucocorticosteroids (mometasone furoate), antihistamines (desloratadine), secretolytics (acetylcysteine) against the background of sanitation of the nasal cavity and paranasal sinuses is the most effective method to significantly improve treatment results.

REFERENCES

- A.I. Kryukov, G.Yu. Tsarapin, S.G. Romanenko, A.S. Tovmasyan, S.A. Panasov. Prevalence and structure of diseases of the nose and paranasal sinuses among the adult population of a metropolis. Russian rhinology, // [The prevalence and structure of diseases of the nose and paranasal sinuses among the adult population of the metropolis] 2017. - No. 1.-P.3-6.
- Volkov A.G. Gentle instrumental treatment of rhinosinusitis (literature review). Russian otorhinolaryngology, // [Sparing instrumental treatment of rhinosinusitis] 2017.-No. 3.-P.86-93. (In Russian).
- A.G. Chuchalin. Pneumonia: An urgent problem in medicine of the 21st century. Pulmonology // [The current problem of medicine of the 21st century. Pulmonology]. 2015; 25 (2): p. 133–142 (In Russian).
- A. S. Lopatin. Acute rhinosinusitis: clinical recommendations // [Acute rhinosinusitis: clinical recommendations]. Russian Society of Rhinologists. – M., 2017. – 36 p. (In Russian).
- Ryazantsev S.V. Acute sinusitis. Approaches to therapy (methodological recommendation). // [Acute sinusitis. Approaches to therapy (methodical recommendation)]. M., 2003. 16 p. (In Russian).
- Abelenda-Alonso G. et al. Influenza and bacterial coinfection in adults with community-acquired pneumonia admitted to conventional wards: risk factors, clinical features, and outcomes //Open forum infectious diseases. – US : Oxford University Press, 2020. – T. 7. – №. 3. – C. 66.
- Achar P., Duvvi S., Kumar B. N. Endoscopic dilatation sinus surgery (FEDS) versus functional endoscopic sinus surgery (FESS) for treatment of chronic rhinosinusitis: a pilot study //Acta Otorhinolaryngologica Italica. – 2012. – T. 32. – №. 5. – C. 314.
- Albiabi S. A. et al. Postnasal Drip Syndrome and Cough, Management and Diagnostic Approach in Primary Health Care Centre //Archives of Pharmacy Practice. – 2020. – T. 1. – C. 127.
- Frei C. R., Labreche M. J., Attridge R. T. Fluoroquinolones in Community-Acquired Pneumonia //Drugs. – 2011. – T. 71. – №. 6. – C. 757-770.
- Hayward G. et al. Intranasal corticosteroids in management of acute sinusitis: a systematic review and meta-analysis //The Annals of Family Medicine. – 2012. – T. 10. – №. 3. – C. 241-249.
11. King L. M. et al. Antibiotic therapy duration in US adults with sinusitis //JAMA internal medicine. – 2018. – T. 178. – №. 7. – C. 992-994.