

MORPHOLOGICAL SUBSTANTIATION OF THE EFFECTIVENESS OF PHOTODYNAMIC THERAPY IN CASE OF WIDESPREAD PERITONITIS IN AN EXPERIMENT

Alisher Sabirmatov

PhD, Tashkent Pediatric Medical Institute, Uzbekistan

Abstract

The article presents the results of experimental studies on the effects on the parietal and visceral peritoneum of intact animals and with simulated widespread peritonitis in white mongrel rats weighing 140-180 g. It was found that methylene blue at a concentration of 0.05% in intact animals at exposure of 5 minutes causes desquamation and small foci of necrosis of mesothelial cells, and in peritonitis against the background of photodynamic therapy has a beneficial effect on reparative processes due to the formation of singlet oxygen. The histological picture of the peritoneum in rats after abdominal sanitation by PDT at all stages of the study was qualitatively better than that of the representatives of the group during abdominal sanitation with 0.02% chlorhexidine solution. Based on the results of morphological studies, the authors recommend that the developed method of photodynamic sanitation of the abdominal cavity be introduced into clinical practice.

Keywords Methylene blue, peritonitis, photodynamic therapy.

INTRODUCTION

Despite the achievements of modern medical science, the issues of prevention, diagnosis and treatment of peritonitis remain relevant. Mortality in acute peritonitis varies from 32.4-45.5% to 50-90% [2,7,9]. Various microorganisms play an essential role in the etiology of peritonitis. In the vast majority of cases, peritonitis is the result of autoinfection, which is usually polymicrobial in nature [3,8,10]. It is known that the successful result of treatment of diffuse purulent peritonitis depends only 15-20% on the effectiveness of antibacterial therapy, and the remaining 80% are associated with adequate surgical tactics, including full sanitation of the abdominal cavity

[8]. It should be noted that the question of the choice of the sanitizing solution remains one of the most controversial, the discussion about the methods of intraoperative sanitation of the abdominal cavity continues to this day [6,7], and according to Gostishchev G, it is advisable to use those solutions that can be administered parenterally [5]. In recent years, the method of photodynamic therapy has been introduced into surgical practice in connection with the bactericidal properties of photosensitizers associated with the formation of singlet oxygen against the background of photochemical reactions. There are publications on the use of photodithiazine, chlorophyllipt, dimegin, etc. as

photosensitizers. The problem of the choice of a photosensitizer for PDT [10], as well as the study of their effect on the ultrastructural elements of the peritoneum in peritonitis [4,7], remains urgent. However, studies on the effect of methylene blue (MS) on the ultrastructure of the healthy peritoneum, and in experimental peritonitis on the inflamed peritoneum, we have not seen. In this regard, the purpose of our study was: to study the effect on the ultrastructural elements of the visceral and parietal peritoneum of methylene blue, 0.02% chlorhexidine, LED radiation and photodynamic therapy in normal conditions and in experimental peritonitis.

METHODS

The experiments were divided into 3 stages: 1) to study the histological structure of the visceral and parietal peritoneum in healthy experimental animals; 2) to study the effects of methylene blue, chlorhexidine and LED radiation on the intact peritoneum separately; 3) to study the effect of 0.02% chlorhexidine solution and photodynamic therapy, i.e., LED radiation and methylene blue at a concentration of 0.05% per peritoneum in experimental peritonitis in a comparative aspect. To create a model of acute experimental widespread purulent peritonitis, we used the technique of Yu.Yu. Blinkov, (RF Patent No. 2338265) [1]. In the group of animals with experimental peritonitis during the operation, the abdominal cavity was drained with suction, then washed with saline. 3 ml of 0.05% methylene blue solution was poured into the abdominal cavity with a syringe and left for 5 minutes, then the solution was removed by suction and PDT was started. The laparotomic wound was sutured through all layers with silk, the animals were marked and placed in standard vivarium conditions. The animals were taken out of the experiment by decapitation immediately after

their introduction into ether anesthesia. As a light source for the PDT session, a domestic-made LED installation "FDU-1" with an output power of 100 mW / cm², a wavelength of 630 ± 20 nm in a continuous red optical range was used. The energy density during the LED irradiation session was 25-35 J / cm², the exposure time was 3-5 minutes. In the control group, the abdominal cavity was sanitized by a similar method as in the main group, then 0.02% chlorhexidine solution was poured into the abdominal cavity, draining. The laparotomic wound was sutured through all layers with silk, the animals were marked and placed in standard vivarium conditions. To study the ultrastructural elements of the visceral and parietal peritoneum, the intestine with the visceral peritoneum in rats was taken in the area of the ileocecal junction (with the visceral peritoneum), the parietal peritoneum in the lateral surface of the abdomen. Pieces of 0.5 1.0 cm in size of the small and large intestines of all experimental animals were fixed in 10-12% neutral formalin with a volume of 0.5 cm³, then washed in running water, dehydrated in alcohols of increasing concentration, impregnated with xelol and embedded in paraffin. Sections were stained with hematoxylin and eosin using a conventional method, fixed with Canadian balsam, and then covered with glass. When viewing and describing the micro preparations, an electronic binocular microscope CYAN was used. Model DN-300M. With 34 MP MICROSCOPE Camera attachment, ocular objective magnification from x = 4x10x0.5, x = 10x0.25x0.5, x = 40x0.65x0.5.

RESULT AND DISCUSSION

At the first stage of our research, we studied the ultrastructural structure of the parietal and visceral peritoneum of healthy outbred white rats. The histological visceral layer consists of mesothelial cells (they originate from a single layer

squamous epithelium). Mesothelial cells produce a secretion - serous fluid (synovial fluid). It provides free sliding between organs and ensures normal

intestinal motility. Figure 1A shows the small intestine.

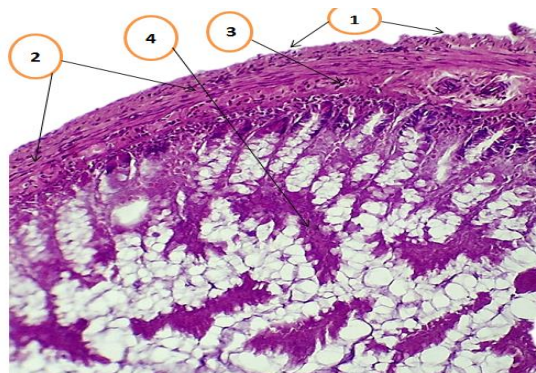
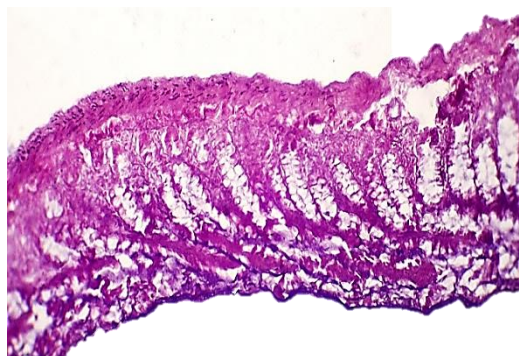
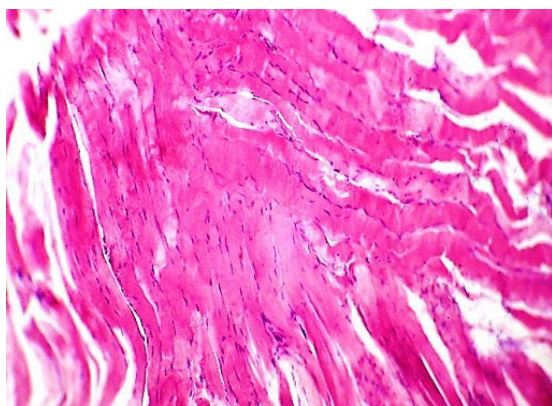
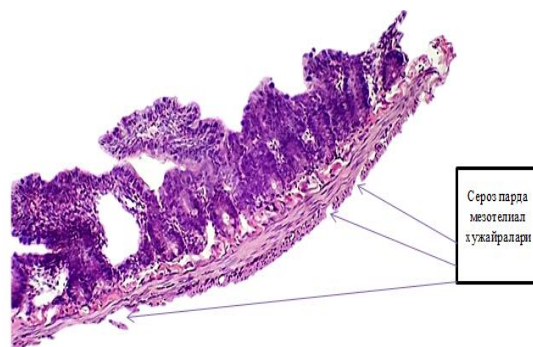


Figure 1.A. Normal small intestine with all layers. Serous membrane, muscle and mucous membranes (with its own plate). G / E coloring. Magnification 10X10. Figure 1B. Normal small intestine. Mesothelial cells of serous foliage (1), muscular membrane in the longitudinal and transverse directions (2), intrinsic plastic of the

mucous membrane (3), villi of the mucous membrane (4). G / E coloring. Magnification 10X10. Figure 1.B shows a normal small intestine with mesothelial cells; the muscularis is presented in the longitudinal and transverse directions. In the striated muscle of the anterior abdominal wall, uneven interstitial edema of the muscular plexuses is noted (Fig. 2A).



A



B

Figure 2A. The striated muscle of the anterior abdominal wall. Uneven interstitial plexus edema. The cross-stripping of muscle cells is preserved.

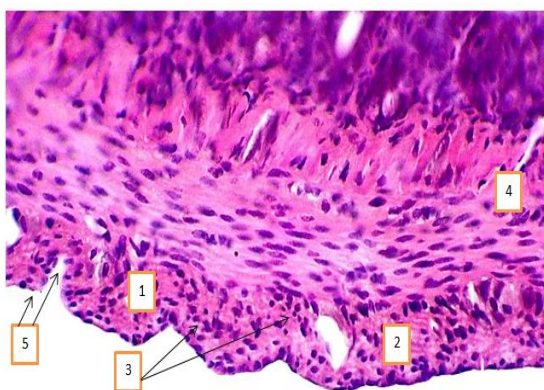
Some cores are enlarged. G / E coloring. Magnification 10X10.

Figure 2B. Small intestine. Serous membrane of

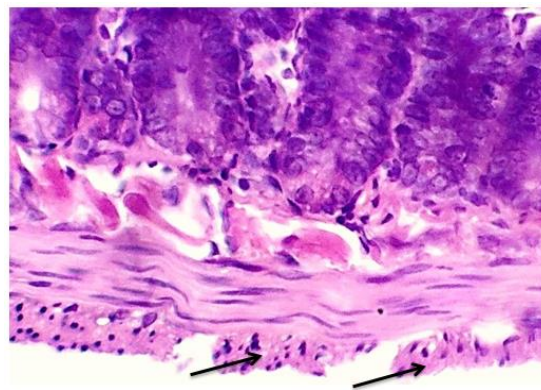
different thickness. The blood vessels are full blooded. The mesothelial cells of the serous membrane have different textures. Desquamation of focal mesothelial cells. G / E coloring. Magnification 10X10.

At stage 2, the effect of 0.05% MS solution on healthy peritoneum (visceral and parietal) of intact animals was studied. MS was injected into the abdominal cavity by puncture of the abdomen in its lower floor with a 3 ml syringe. Due to the fact

that MS is used in medicine as an antiseptic and is also an oxidant, it causes some changes in organs and tissues. So, when MS is injected into the abdominal cavity, the mucopolysaccharides of the serous fluid interact and promotes the formation of acidic glycosaminoglycans. In this regard, the number of mesothelial cells decreases, the latter are labile cells (actively multiplying). As a result, MS begins to exert cytostatic and cytotoxic effects. These changes are presented in Figures 2B, 3A.



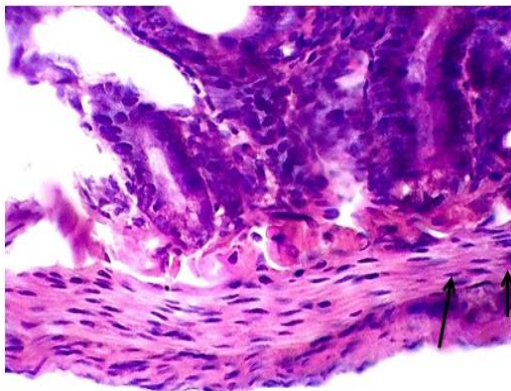
A



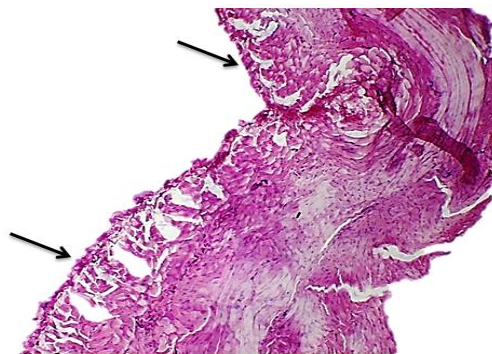
B

Figure 3A. The impact of MS on the serous membrane of the small intestine is marked by desquamation and necrosis of mesothelial cells, in defective places, proliferation and uneven arrangement of mesothelial cells are observed. Figure 3B. Erosive-necrotic changes in the serous membrane of the small intestine under the

influence of MS. G / E coloring. Magnification 60X10. There are multiple recovery processes in the foci of desquamation (3B, 4A). They are indicated by arrows. In the patient's own plastics, uneven edema is noted, in plastics of the connective tissue, fibrinoid swelling and focal fibrinoid necrosis. G / E coloring. Magnification 40X10.



A

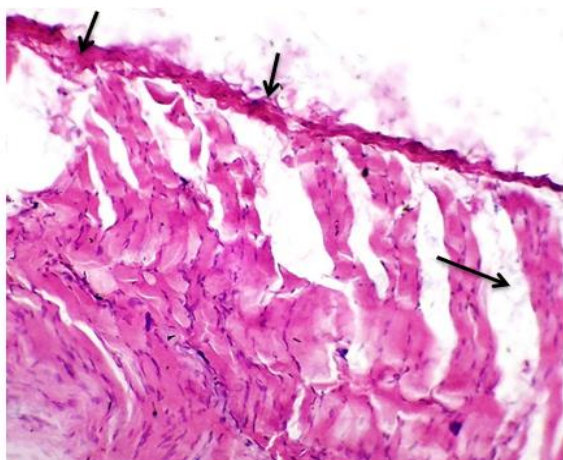


B

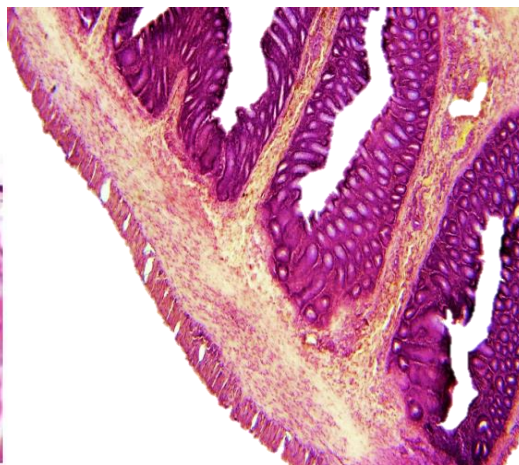
Figure 4A. In the bare surfaces of the serous membrane of the small intestine, under the influence of MS, scar surfaces of transformed fibroblasts are formed. They are shown by arrows. Figure 4B. The striated muscle of the anterior abdominal wall. On the side of the parietal peritoneum, there are multiple foci of fibrinoid necrosis. Indicated by an arrow. Dystrophic changes are observed in the striated muscles, the

transverse is lost. G / E coloring. Magnification 10X10.

Figures 4B - 5A show that MS on the parietal peritoneum of healthy animals cause fibrinoid necrosis; however, below ultrastructural changes in animals with peritonitis will be presented, when MS, on the contrary, enhances proliferative processes.



A



B

Figure 5A. In the parietal peritoneum (in the structures of the basal layer of fine-fibrous

connective tissue), fibrinoid swelling, desquamation of mesothelial cells are noted, they

are indicated by arrows, there are interstitial edema of different sizes between the muscle bundles, different staining of the dystrophic altered cytoplasm. G / E coloring. Magnification 40X10. Figure 5B. Colon after exposure to PDT with MS. The serous membrane contains many tortuous and hyperplastic mesothelial cells (1). The muscular membrane of the same texture, not pronounced interstitial edema (2). The mucous membrane and its own plate are full-blooded. In the general background, the histioarchitectonics of the tissue is absolutely unchanged.

Thus, in healthy experimental animals, when MS is injected into the abdominal cavity, a focal one is

observed on the surface of the serous membrane, or massive foci of desquamation are determined in places of a large accumulation of MS. In the blood vessels of the visceral peritoneum there is uneven plethora, on the basal plate there are bare areas, the transformation of macrophages into fibroblasts and the formation of adhesions, in the vessels of muscles there is uneven plethora, dystrophic changes in the muscles, in the lamina propria there is interstitial edema, foci of mucoid swelling in the vasculature. At the 3rd stage of the study, we studied morphological changes in the parietal and visceral peritoneum under the influence of PDT with MS in experimental peritonitis (Fig. 5B, 6A).

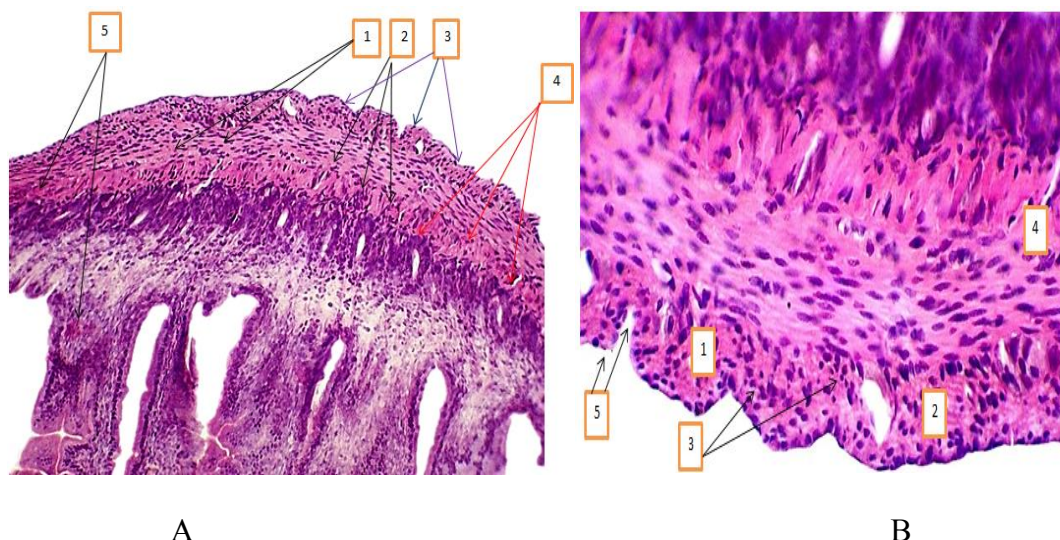


Figure 6A. Condition after PDT with MS. On the cut of the small intestine. The visceral peritoneum is of varying thickness, clearly basophilic. Interstitial edema to varying degrees (1). Full-blooded capillaries (2). Increased proliferation of (3) mesothelial cells. Basement membrane of uneven thickness (4). There is obvious plethora in the muscle layer and in the lamina propria (4). Figure 6B. Visceral peritoneum after PDT with MS. There

is plethora in the vessels of the visceral peritoneum (1). Intensive proliferation of mesothelial cells of the visceral peritoneum (2). A group of not yet formed mesothelial cells (3). Congestion in the lamina propria of the muscular and mucous membranes (4). Due to proliferation, the surface is tortuous. G / E coloring. Magnification 10X10.

Thus, under the influence of PDT with MS in experimental peritonitis, the following changes

were revealed: firstly, due to the release of singlet oxygen during a photochemical reaction, it can damage the membranes of any cells and cause a necrotic process. If a cell contains a large number of mitochondria, singlet oxygen is involved in the Krebs cycle and utilized by mitochondria. These properties are mainly observed in organs formed (parenchymatosis) from the epithelial cell. It is due to the fact that mesothelial cells by origin are epithelial in nature, they are not significantly damaged and due to the increase in the proliferative properties of the mesothelial layer cell, proliferative processes occur. Their number is increasing, they are multi-row and one-story (Fig. 6A, 6B); Secondly, due to the release of singlet oxygen from the sensitized molecule, the membranes of the infectious agent are damaged and, as a result, the inflammatory process fades away; Thirdly, fibroblasts, the main component of

which is connective tissue, by origin, which are mesenchymal tissues, containing a small number of mitochondria, their resistance to PDT and a decrease in proliferation, the plate of mesothelial cells thickens (Fig. 6A); Fourthly, there is a decrease in the activity of the inflammatory process; in the lamina propria of the muscular and mucous membrane, a reaction of macrophageal infiltration is noted (Fig. 6A, 6B). The accumulation of basophilic stained cells is determined; fifthly, the exudative phase of inflammation fades away, since reparative processes (restoration of damaged tissues) are enhanced under the influence on the surface of damaged tissues. Morphological changes in the parietal and visceral peritoneum after the introduction of 0.02% chlorhexidine solution into the abdominal cavity were as follows (Fig. 7A, 7B):

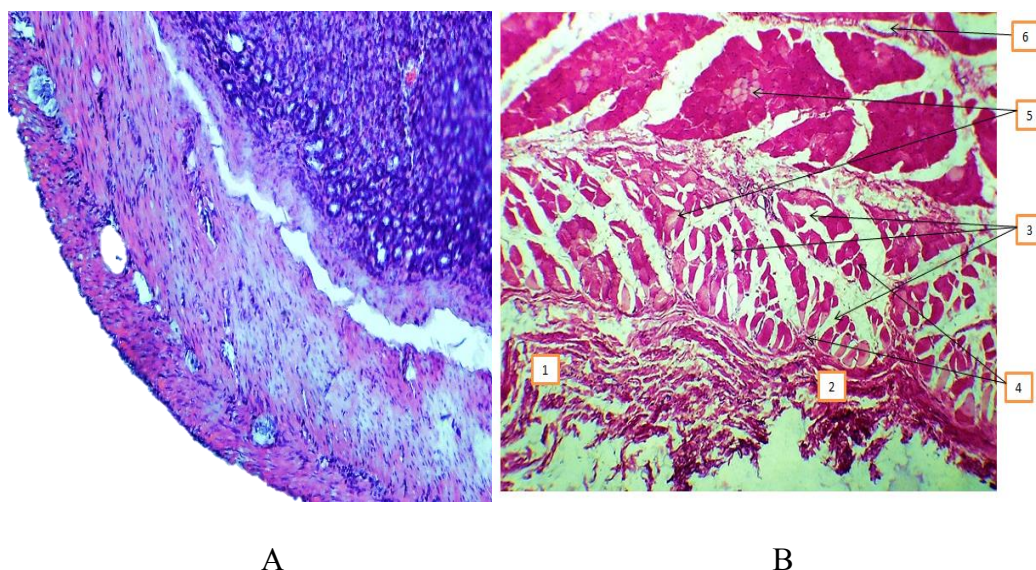


Figure 7A. Part of the colon. Serous membrane (visceral leaf), the surface is uneven, tortuous (1). There are many foci of neutrophilic infiltration between the muscular membrane (2). There is

swelling in the lamina propria of the mucous membrane (3). In the mucous and submucosal layers vascular congestion. Figure 7B. The striated muscle and parietal peritoneum after exposure to

0.02% chlorhexidine solution. Components of the parietal peritoneum: destruction in fiber structures, disorganization, necrosis (1). Congestion in the vessels (2). In the interstitium of muscle tissue, uneven edema (3), in Andy's muscle

plexuses, foci of emerging foci of fragmentation and decomplexation are determined (4), myocytes are focally chromophobically stained (5), zones of forming thin-fibrous connective tissue are determined in interstitial spaces (6).

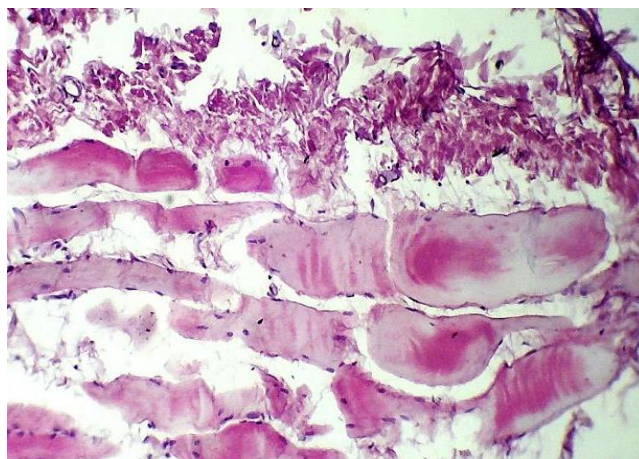


Figure 8. Changes after exposure to chlorhexidine. Disorganization and destruction of the components of the parietal peritoneum. The muscular plexuses lose their striation. The cells are chromophobic stained. Incession is unevenly edematous. In the interstitium, fine-fibrous connective tissue connective tissue is formed. Myocyte nuclei are reduced. The foci of lymphocytic infiltration are determined. Rom the presented figures 7B, 8 it follows that 0.02% chlorhexidine solution in healthy animals in the parietal peritoneum causes destruction in fiber structures, disorganization and necrosis. In the muscular plexuses, the zones of forming foci of fragmentation and decomposition are determined.

Rom the presented figures 7B, 8 it follows that 0.02% chlorhexidine solution in healthy animals in the parietal peritoneum causes destruction in fiber structures, disorganization and necrosis. In the muscular plexuses, the zones of forming foci of fragmentation and decomposition are determined. The muscular plexuses are likely to be affected due to the absorption of chlorhexidine. It should be

noted that in the work of S.A. Pusty. it was shown about the toxic effect of 0.05% chlorhexidine solution on the parietal and visceral peritoneum, even on the functional state of the liver and spleen [5]. Thus, in healthy experimental animals, when MS is injected into the abdominal cavity, a focal one is noted on the surface of the serous membrane, especially in places of a large accumulation of MS, massive foci of desquamation are determined. Meanwhile, with experimental peritonitis, i.e. with a damaged peritoneum, due to the formation of singlet oxygen against the background of a photochemical reaction, cell membranes can be damaged, however, if the cell contains a largenumber of mitochondria, oxygen is involved in the Krebs cycle and is utilized by mitochondria. These properties are mainly observed in organs formed from the epithelial cell. Mesothelial cells are epithelial in origin and contain a large number of mitochondria, and in this regard, proliferative processes in the cells of the mesothelial layer are activated. Consequently, mesothelial cells are less susceptible to damage. The results of morphological studies clearly confirm the

differences in the results of intraoperative sanitation of the abdominal cavity and treatment of experimental fecal peritonitis in rats with PDT using MS in comparison with the group with sanitation with 0.02% chlorhexidine solution. The histological picture of the peritoneum in rats after abdominal sanitation by PDT at all stages of the study was qualitatively better than in the representatives of the group after abdominal sanitation with 0.02% chlorhexidine solution. Moreover, dystrophic and destructive changes in the mesothelial layer, edema and vascular disorders in the main group are less pronounced.

Findings

1. Methylene blue and LED radiation in the red range with a wavelength of 630 ± 20 nm, with a power density of 100 mW / cm², an energy density of 25-35 J / cm², an exposure duration of 3-5 minutes, individually and in combination, cause desquamation, plethora vessels of the visceral and parietal peritoneum of intact animals, but the mesothelial cells contain a large number of mitochondria and they utilize singlet oxygen, and therefore the damage is not significant. Moreover, proliferative processes are induced in the cells of the mesothelial layer.

2. Aqueous 0.02% chlorhexidine solution, when administered into the abdominal cavity of animals, has a damaging effect on the visceral and parietal peritoneum. This is expressed in the following: destruction of fiber structures, disorganization, necrosis, plethora in the vessels, uneven edema in the muscular plexuses, and in the plexuses of Andy, foci of emerging foci of fragmentation and decomplexation are determined.

3. In conditions of acute experimental widespread purulent peritonitis, photodynamic sanitation of the abdominal cavity with methylene blue at a concentration of 0.05% with LED radiation with a

wavelength of 630 ± 20 nm, with a power density of 100 mW / cm², an energy density of 25-35 J / cm², duration

4. Exposure 3-5 minutes showed that the histological picture of the peritoneum in dynamics is better with PDT in comparison with 0.02% chlorhexidine solution. The availability of methylene blue, the reliability, the simplicity of the method, the exclusion of the damaging effect of the combination of photodynamic action with MS allows us to conclude that the method of photodynamic sanitation of the abdominal cavity can be introduced into clinical practice.

REFERENCES

1. Blinkov Yu.Yu. Pathogenetic substantiation of methods of complex treatment of widespread peritonitis (experimental clinical study) // Abstract of the thesis. Diss. Doctor of Medical Sciences-2012. -Kursk. -P.32.
2. Vlasov A.P. A new scheme for the correction of the syndrome of endogenous intoxication in emergency surgery [Text] / A.P. Vlasov, V.A. Bolotskikh, O.V. Markin et al. // Materials of the All-Russian Surgical Forum - 2019 in conjunction with the XXII Congress of the Society of Endoscopic Surgery of Russia (ROEH named after Academician V.D. Fedorov). - Moscow, 2019.-- pp. 132 - 133.
3. Gelfand B.R. et al. Ways to optimize antimicrobial therapy of abdominal surgical infections in conditions of increasing antibiotic resistance / B.R. Gelfand, B.Z. Belotserkovny, T.V. Popov // Infections in surgery. - 2015. - T. 13. - No. 2. - P. 36-47.
4. Ostrovskaya O.B., Rusin V.I., Smotrin S.M. The influence of photosensitizers on ultrastructural elements of the peritoneum in the experiment. News of surgery. -2011. T.19.- №4.-C.3-9.

5. Pusty S.A. Clinical and experimental evaluation of the use of nitrogen monoxide containing gas flow in the sanitation of the abdominal cavity with widespread purulent peritonitis // Abstract of the thesis. Candidate of Medical Sciences. - Stavropol.-2018.-P.27.
6. Rusin V.I., Zimatkin S.M., Smotrin S.M. Histological assessment of the peritoneum of rats with experimental peritonitis and its treatment with photodynamic therapy // Journal of the Grodno State Medical Institute.- 2011.-No.3.-P.21-24.
7. Kirkpatrick A.W. Closed or Open after Source Control Laparotomy for Severe Complicated Intra-Abdominal Sepsis (the COOL trial): study protocol for a randomized controlled trial [Text] / A.W. Kirkpatrick, F. Coccolini, L. Ansaloni et al. // World J Emerg Surg. — 2018. — Vol.13. – P. 26.
8. Saveliev, V.S. Assessment of the severity of damage to the abdominal organs in peritonitis [Text] / V.S. Saveliev, B.R. Gelfand, M.I. Filimonov // Infections in surgery. - 2013. No. 2. - S. 5-9.
9. Muller V. The treatment of acute secondary peritonitis: A retrospective analysis of the use of continuous negative pressure therapy [Text] / V. Muller, G. Koplín, J. Pratschke et al. // Med Klin Intensivmed Notfmed. — 2018. — Vol.113. – №4. – P. 299 – 304.
10. Virych P.A., Nadtoka O.M., Virych P.A., Ku. N.V. Photoinactivation of staphylococcus aureus in vitro by red light (660 nm) in the presence of methylene blue|| Photobiology and experimental photomedicine/ Photobiol Photomed. - 28.-2019.-p.66-73.