



Journal Website:
<http://usajournalshub.com/index.php/TAJMSPR>

Copyright: Original content from this work may be used under the terms of the creative commons attributes 4.0 licence.

New Approaches In The Diagnosis Of Oral Hemangiomas

Karimov M.A.

Doctorate, Department of Oncology and Medical Radiology, Andijan State Medical Institute, Andijan, Uzbekistan

Mamrasulova D.Z.

Doctor of science, docent, head of department of Oncology and Medical Radiology, Andijan State Medical Institute, Andijan, Uzbekistan

Sadykov R.R.

Doctor of science, docent, department of surgical diseases, Tashkent Medical Academy, Tashkent, Uzbekistan

Nurmatova Kh.Kh.

Assistant, Kasansai technical school of social health named after Abu Ali Ibn Sina, Kasansai, Namangan, Uzbekistan.

ABSTRACT

Scientific work was carried out on the basis of the Tashkent Medical Academy, Department of Surgery (1st city hospital), and Andijan Medical Institute, Department of Oncology from 2015-2020. Clinical material includes 175 patients. The comparison group consisted of 100 patients who were treated in various hospitals in Tashkent and regions of Uzbekistan. According to the classification of vascular anomalies, the majority of patients with benign vascular tumors (DBT) were diagnosed with infantile hemangioma (IG) - 82.0%, congenital hemangioma (VH) - 11.4%, pyogenic granuloma (PG) - 5.8%. Average age of patients: children - 1.2 ± 0.4 , adults - 27 ± 1.2 years. The frequency of DSO in girls was 78%, in boys - 22%. Localization area: lip - 57.6%, cheek 8%, tongue 26.3%. Complications of DSO: anatomical disorders, edema, bleeding, pain, infection, respiratory disorders occurred in 83.7% of patients.

KEYWORDS

Hemangioma, oral cavity, children

INTRODUCTION

Hemangiomas of the oral cavity (Oral cavity) are one of the types of vascular tissue tumors

characterized by rapid growth and invasion of the surrounding tissues. Unlike other tumors,

the peculiarity of fracturing is the absence of the facts of malignant transformation, as well as its ability to undergo phases of growth and involution [1]. The classifications used to this day (Kondrashkin, 1963), which unites all types of vascular anomalies under the term hemangioma, are based on the morphological structure of formations and do not take into account the peculiarities of their growth and development. This often leads to inappropriate treatment tactics. For example, in the case of actively proliferating hydraulic fractures, expectant tactics promote excessive tumor growth with invasion into the surrounding tissues, and surgical activity in the stage of tumor regression is excessive and leads to anatomical and functional defects, bleeding during surgery [4,6].

Malformations have a similar course in HF, but unlike them, they do not undergo phasic development and do not have a tendency to spontaneous involution, steady growth and invasion of the surrounding tissues can lead to complications, deformations, and loss of organ function [1,7].

The final diagnosis of a fracture can be made after histology, for which a biopsy is required. However, in clinical practice, biopsy, as a rule, is not used, due to the fact that most patients of early childhood, manipulation should be carried out under general anesthesia, and there is a high likelihood of developing uncontrolled bleeding from the dilated hemangioma vessels [10]. The experience of leading foreign clinics dealing with the problems of vascular anomalies has convincingly demonstrated the need for their differentiation by anatomical structure, blood flow, growth characteristics, and developmental phases. A distinction should be made between vascular abnormalities in the form of malformations and benign

vascular tumors. The peculiarity of clinical diagnostics is the need to use modern radiation imaging methods, as well as to carry out special histochemical studies (ISSVA, 1996). However, in the case of hydraulic fracturing diagnostics, methods have not been developed to determine the degree of proliferative growth. This factor is fundamental in the choice of treatment tactics for this category of patients [3].

PURPOSE OF THE STUDY

We have set the task of developing new methods for determining the proliferative activity of hydraulic fracturing, assessing the reliability of diagnostics based on the data of complex studies, as well as adapting diagnostic methods to the conditions of medical institutions in our country.

In our research, we adhered to the main provisions of the international classification based on the research of A. Mulliken, 1996.

MATERIALS AND METHODS

We have developed a new algorithm for the diagnosis and choice of treatment tactics for oral hemangiomas, which is based on a number of diagnostic criteria.

Taking into account the fact that most clinics do not have the ability to conduct histochemical studies, we combined congenital hemangiomas into one group, and the treatment tactics were determined depending on the degree of tissue proliferation after the started course of conservative therapy.

The algorithm for the diagnosis of benign vascular tumors is included in the computer processing program, thereby significantly facilitating the assessment of research results and diagnosis.

In the primary diagnosis of DSO, it is important to correctly collect anamnesis and clinical examination of the patient. Data such as sex, concomitant diseases, mother's illness during pregnancy, time of hemangioma appearance, localization, size, growth rate, prevalence, color intensity, the influence of factors provoking growth, degree of invasion into surrounding tissues, blood flow rate are important. Fracturing is characterized by the onset of the disease from the birth of a child, progressive proliferative growth, stabilization, and in some cases spontaneous involution, lack of tendency to malignancy.

In view of the fact that hydraulic fractures are outwardly very similar to vascular malformations, it becomes necessary to use additional diagnostic methods.

Ultrasound examinations are carried out to assess the structure of soft tissues, the degree of blood supply. Color Doppler ultrasound accounts for up to 90% of the studies.

MRI, MSCT, angiography, more complex research methods are indicated if multiple lesions are suspected, especially with the involvement of internal organs and the brain.

Histological verification was performed for definitive diagnosis and exclusion of malignant tumors.

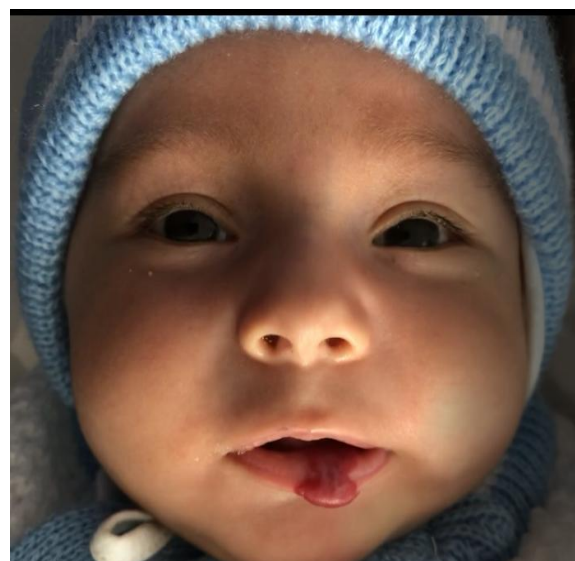
Infantile hemangioma is the most common pathology of the DSO. It is necessary to distinguish 5 phases of the development of IG: prodromal, initial, proliferative, maturation, regression

RESULTS AND DISCUSSION

Infantile hemangioma (IH) (Fig. 6) usually appears several days or weeks after birth. In some cases, prodromal signs are limited telangiectasia, anemia, reddish-blue or blue

spots, and wine stains. Sometimes they do not appear, in particular, in newborns with high hematocrit or hyperbilirubinemia. Color duplex ultrasound scanning (CDS) may not reveal a typical picture, but in cases of intradermal localization, destruction of the two-layer structure of the dermis is observed.

In the early or initial phase, the infantile hemangioma may partially appear within a few days. Depending on the type of growth, limited or infiltrative, it can be diffuse, infiltrating the surrounding tissues or, in the case of limited growth, has clear boundaries (Fig. 7). The latter protrudes above the level of the skin, has a bright red color, forcing parents to consult a doctor sooner than with infiltrative forms of hemangiomas. In CDS, only a diffuse hypoechoic structure is often detected, similar to the picture with a fresh hematoma without visible vessels or capillarization. With intradermal hemangiomas, the typical two-layer skin structure disappears (Fig. 2).



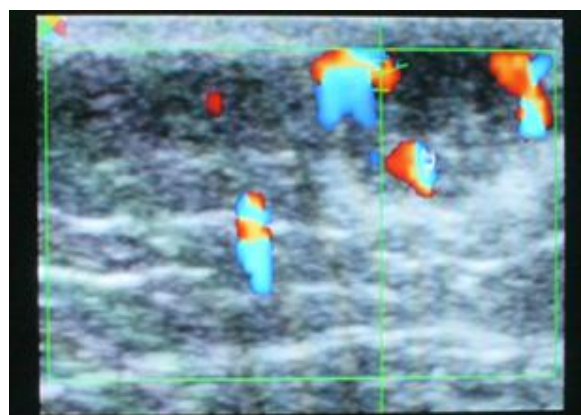


Fig. 2. Patient A. Age - 3 months. Diagnosis: infantile hemangioma of the lower lip, initial phase (a), and ultrasound picture - hypoechogenicity in the center of education (1); increase in thickness, and start of compaction. Edge hypervascularization (2) (b)

During the phase of proliferation, the hemangioma grows at different rates

exophytic or endophytic-subcutaneously, and sometimes in combination (Fig. 2). Hemangiomas with limited growth usually grow minimally. Subcutaneous hemangiomas appear later and grow over a longer period of time. The coexistence of two forms is quite possible, in which each has its own characteristic of growth. With CDS, an increase in capillary blood flow is visualized. The more pronounced the blood flow, the more active the growth of hemangioma. Thus, CDS is a method for assessing the activity and aggressiveness of infantile hemangioma. In addition to hyperechoic zones that are already regressing, hypoechoic, early proliferating zones may exist in the same hemangioma. In the case of the excessively rapid growth of IG, the underdevelopment of medium-sized vessels can lead to trophic disorders with ulceration (Fig. 3).

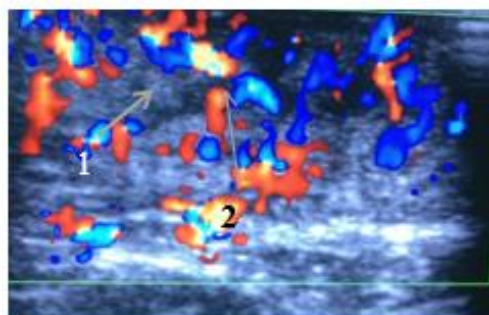
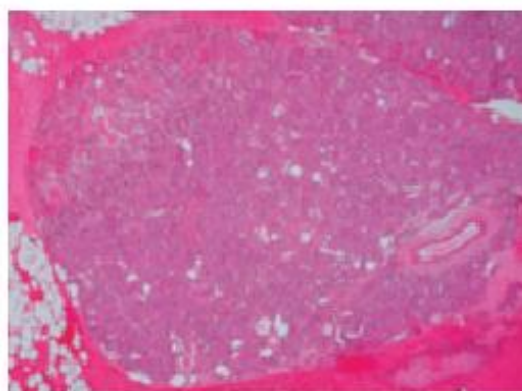
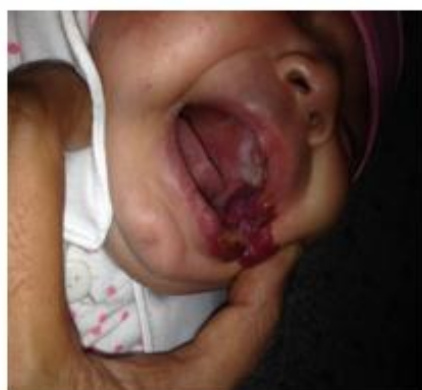

Fig. 3. Patient A. 6 months, Diagnosis: infantile hemangioma of the upper and lower lips, proliferation phase (a, b), ultrasound picture. Increased intratumoral hyperperfusion; increased vascularization. The supplying vessels are located in the center of the tumor. (1) Drainage veins with arterialization appear (2) (c), the histological structure is the presence of loose, rapidly dividing endothelial cells that form a mass of sinusoidal vascular canals. The formation is vascularized by large feeding arteries and draining veins (d).

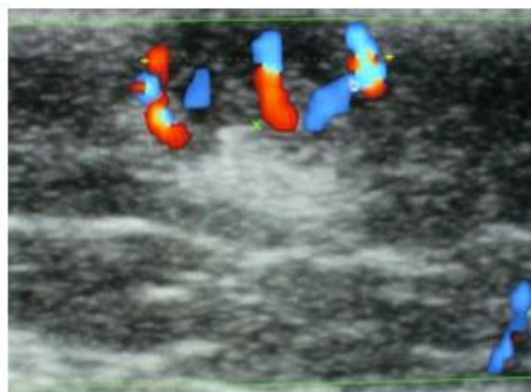
The histological picture of infantile hemangioma in the proliferation phase is characterized by hyperproliferation of endothelial cells. The connective tissue layer is poorly expressed. The vessels around are abnormally changed. In this case, the vascular stroma is normal.

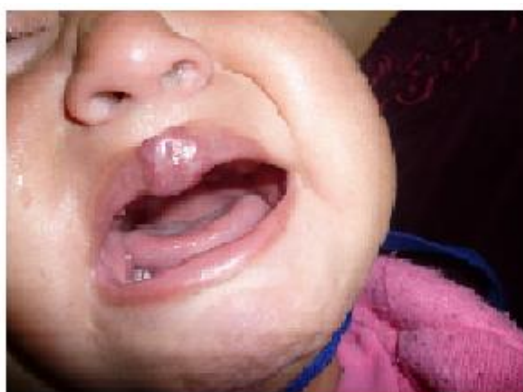

Fig. 4. Patient C. 6 months., Diagnosis: infantile upper lip, maturation phase (a), ultrasound picture Appearance of hyperechogenicity in the center of the tumor, decreased vascularization, increased ectasized drainage veins (1); decrease in arterialization of drainage veins (b).

The regression phase usually ends by age six. Localized cutaneous hemangiomas are more prone to regression than infiltrating cutaneous or subcutaneous hemangiomas

In the maturation phase, the growth of IG stops. With intradermal hemangiomas, the size is reduced and the epidermis shrinks accordingly (Fig. 9). In addition, areas of blanching appear in the dark red zone of the IG. The fabric becomes less elastic. Ultrasound reveals areas of hyperechogenicity, as signs of maturation. Duplex scanning, on the one hand, shows that the microcirculation decreases, on the other, drainage veins are formed, which are directed vertically to the surface. If during this period a histological examination is carried out, then large veins with a single-layer endothelium can be found, which is often characteristic of malformations. Due to the stealing effect, ischemic zones appear in the skin with the formation of ulcerations (Fig. 4).



(Fig. 10). CDS in these cases reveals hyperechogenicity, as a manifestation of fibrolipomatous transformation. Large residual venous vessels can remain in places for a long time. They are secondary in nature and have a normal structure of the vessel wall. Small hemangiomas, which are at the end of the maturation phase and the beginning of regression, do not cause secondary damage to the surrounding tissues and are completely healed without residue. Large hemangiomas

often leave telangiectasias, areas of atrophic, wrinkled skin, sagging skin, hyper- or hypopigmentation, or drooping abdomen as fibrolipomatous tissue. The more

hemangioma before entering the stage of regression, the greater the residual effects (Fig.5).

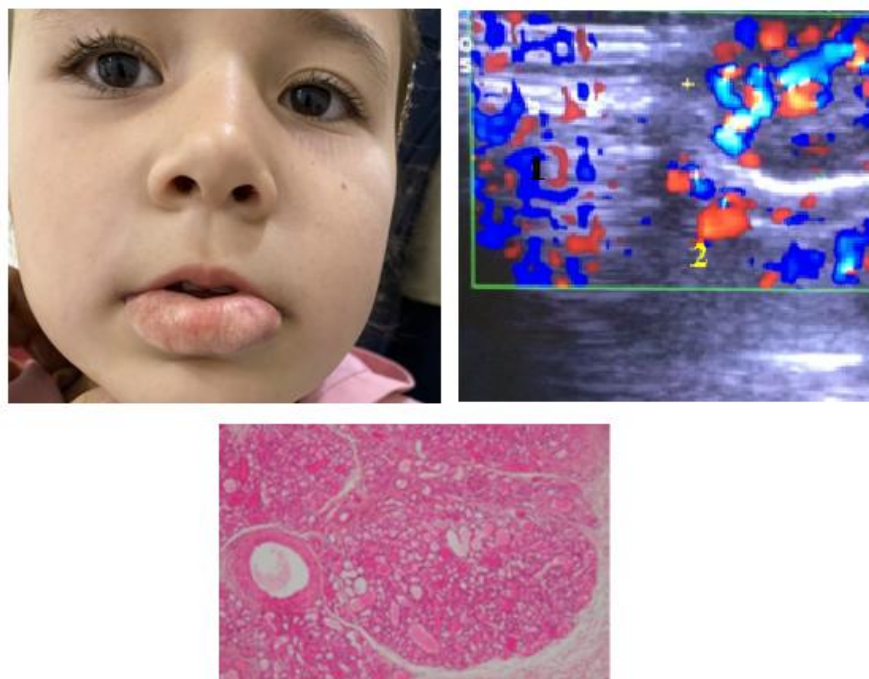


Fig. 5. Patient V., 1-year-old. Diagnosis: infantile hemangioma of the lower lip, regression phase (a), ultrasound picture. Revealed hyperechoic zone (1); loss of typical tissue structure, lack of central blood flow; residual tumor feeding arteries; residual ectasized drainage veins (2) (b), the histological structure is characterized by a gradual decrease in endothelial activity, reduction of angiogenesis, apoptosis of endothelial cells, dilation of vascular canals, lobular architectonics, replacement of fibro-fatty stroma and small capillaries (c).

CONCLUSIONS

The developed new algorithm for the diagnosis of benign vascular tumors makes it possible to establish their shape, stage of development, and proliferative activity;

differentiate with malformations and other types of vascular tumors (sensitivity 100%, specificity 94.4%).

The developed algorithm of treatment tactics takes into account the types, forms, and stages of fracture development is effective in children and adults and make it possible to achieve complete healing of fractured fractures.

The histological picture is characterized by obvious visualization of normal vessels, against the background of endothelial cells filled with stroma. Thus, the differentiation of the phases of the development of IH is possible by modern research methods and is important in the choice of treatment tactics.

REFERENCES

1. Abdolrazaghi, H., Riyahi, A., & Zamenjany, M. R. (2020). Large venous hemangioma of brachial plexus. *Ann Card Anaesth*, 23(2), 218-220. Retrieved from <https://www.ncbi.nlm.nih.gov/pubmed/32275040>. doi:10.4103/aca.ACA_73_18
2. Adamski, A., Qian, J., & Adamo, M. A. (2020). Giant Intracranial Extraaxial Parietal-Occipital Cavernous Hemangioma in an Adolescent. *World Neurosurg*, 141, 3-7. Retrieved from <https://www.ncbi.nlm.nih.gov/pubmed/32474102>. doi:10.1016/j.wneu.2020.05.188
3. Al-Rwebah, H., Alkhodair, R., & Al-Khenaizan, S. (2020). Propranolol-induced hyperkalemia in the management of infantile hemangioma. *JAAD Case Rep*, 6(4), 359-361. Retrieved from <https://www.ncbi.nlm.nih.gov/pubmed/32258322>. doi:10.1016/j.jdc.2020.01.028
- Alghamdi, B., Al-Kadi, M., Alkhayal, N., Alhedaithy, R., & Al Mahdi, M. J. (2020). Intranasal lobular capillary hemangioma: A series of five cases. *Respir Med Case Rep*, 30, 101073. Retrieved from <https://www.ncbi.nlm.nih.gov/pubmed/32455105>. doi:10.1016/j.rmcr.2020.101073
4. Alsaid, R. Q., & Al-Musalhi, B. H. (2020). Progressing eczematous dermatitis in an infantile hemangioma with minimal or arrested growth treated with tacrolimus ointment. *JAAD Case Rep*, 6(6), 572-573. Retrieved from <https://www.ncbi.nlm.nih.gov/pubmed/32509952>. doi:10.1016/j.jdc.2020.04.031
5. Bagheri, A., Feizi, M., & Tavakoli, M. (2020). Unusual Subcutaneous Presentation of Cavernous Hemangioma in the Lower Eyelid. *J Ophthalmic Vis Res*, 15(2), 236-239. Retrieved from <https://www.ncbi.nlm.nih.gov/pubmed/32308958>. doi:10.18502/jovr.v15i2.6741
6. Barrett, A. W., & Speight, P. M. (2000). Superficial arteriovenous hemangioma of the oral cavity. *Oral Surg Oral Med Oral Pathol Oral Radiol Endod*, 90(6), 731-738. Retrieved from <https://www.ncbi.nlm.nih.gov/pubmed/11113819>. doi:10.1067/moe.2000.108806
7. Bekdemir, S., Gunduz, A. K., & Ersoz, C. C. (2020). Orbital Cavernous Hemangioma Presenting with a Dome-Shaped Maculopathy-Like Appearance on Swept-Source Optical Tomography Imaging. *Case Rep Ophthalmol Med*, 2020, 5354609. Retrieved from <https://www.ncbi.nlm.nih.gov/pubmed/32274232>. doi:10.1155/2020/5354609
8. Bel Hadj, M., Marzougui, M., Ben Abdeljelil, N., Dhouieb, R., Zakhama, A., & Chadly, A. (2020). Spontaneous Rupture of a Hepatic Cavernous Hemangioma: A Rare Case of Sudden Unexpected Death. *Am J Forensic Med Pathol*, 41(2), 138-140. Retrieved from <https://www.ncbi.nlm.nih.gov/pubmed/32379098>. doi:10.1097/PAF.0000000000000552
9. Book, M., Faatz, H., & Lommatzsch, A. (2020). [Differential diagnosis of papilledema and macular exudation-the exophytically growing juxtapapillary retinal capillary hemangioma]. *Ophthalmologe*. Retrieved from <https://www.ncbi.nlm.nih.gov/pubmed/32577810>. doi:10.1007/s00347-020-01138-x
10. Boparai, R. S., Maeng, M. M., Dunbar, K. E., Godfrey, K. J., Tooley, A. A., Maher, M., & Kazim, M. (2020). Comparing Image Segmentation Techniques for Determining 3D Orbital Cavernous Hemangioma Size on MRI. *Ophthalmic Plast Reconstr Surg*. Retrieved from <https://www.ncbi.nlm.nih.gov/pubmed/32427734>. doi:10.1097/IOP.0000000000001651

-
11. Cai, W. L., Ma, X. M., Sun, X. H., Ren, T., Huang, C. Y., Li, Y. S., . . . Peng, S. Y. (2020). Surgical indication and strategy for liver hemangioma in the caudate lobe: a multi-institutional retrospective analysis with 137 patients. *World J Surg Oncol*, 18(1), 123. Retrieved from <https://www.ncbi.nlm.nih.gov/pubmed/32522218>. doi:10.1186/s12957-020-01901-z