


Dermoscopy and Wood's Lamp Compared with Potassium Hydroxide Microscopy in Pityriasis Versicolor: A Cross-Sectional Diagnostic Accuracy

 **Christabel A. Ovesuor, FWACP**

Department of Internal Medicine, Federal Medical Center, Asaba; and Department of Interdisciplinary Studies and Statistics, PENKUP Research Institute, Birmingham, United Kingdom.

Uche Rowland Ojinmah, FMCP

Dermatology Sub-Department; University of Nigeria Teaching Hospital, Enugu State, Nigeria

Gladys Ozoh, FWACP

Dermatology Sub-Department; University of Nigeria Teaching Hospital, Enugu State, Nigeria

 **Kennedy Oberhiri Obohjemu, PhD**

Department of Interdisciplinary Research and Statistics, PENKUP Research Institute, Birmingham, United Kingdom.

 **Celestine Emeka Ekwuluo, MPH**

Family Health International, Ukraine; and PENKUP Research Institute, Birmingham, United Kingdom; Department of Multidisciplinary Studies & Statistics, PENKUP Research Institute, Birmingham, United Kingdom.

 **Kenechi Gerald Ike, FMCPPath**

Department of Anatomic Pathology and Forensic Medicine, Nnamdi Azikiwe University Teaching Hospital, Nnewi, Anambra State, Nigeria; and Department of Interdisciplinary Research & Statistics, PENKUP Research Institute, Birmingham, United Kingdom.

 **Festus Ituah, PhD**

School of Health and Sports Science, Regent College, London, United Kingdom; and Department of Interdisciplinary Research & Statistics, PENKUP Research Institute, Birmingham, United Kingdom.

Kingsley Chike Madubuike, FMCPPath

Histopathology Department, Faculty of Basic Clinical Sciences, College of Medicine, Chukwuemeka Odumegwu Ojukwu University, Awka, Anambra State, Nigeria; and Department of Interdisciplinary Research & Statistics, PENKUP Research Institute, Birmingham, United Kingdom.

 **Oluwapelumi Silvanus Ajayi, MBChB**

Department of Interdisciplinary Research & Statistics, PENKUP Research Institute, Birmingham, United Kingdom.

Corresponding Author: Dr. Kennedy Oberhiri Obohjemu, Senior Researcher & Project Coordinator, PENKUP Research Institute, Birmingham, United Kingdom. <https://orcid.org/0000-0001-5175-1179>, Kennedy.Obohjemu@penkup.com

Received: 19 Jan 2026 | Received Revised Version: 26 Feb 2026 | Accepted: 26 Mar 2026 | Published: 16 Apr 2026

Volume 08 Issue 04 2026 | Crossref DOI: 10.37547/tajas/Volume08Issue04-04

ABSTRACT

Background: *Pityriasis versicolor* is a common superficial fungal infection caused by *Malassezia* species. Diagnosis is often clinical, with confirmation through potassium hydroxide microscopy or Wood's lamp examination. Dermoscopy has emerged as a non-invasive diagnostic tool, yet evidence from Sub-Saharan Africa remains limited.

Objective: To evaluate the diagnostic performance of dermoscopy compared with Wood's lamp, using potassium hydroxide microscopy as the reference standard.

Methods: A hospital-based cross-sectional study was conducted among 113 adult patients with clinically diagnosed *pityriasis versicolor* at a tertiary dermatology clinic in South-East Nigeria. All participants underwent Wood's lamp examination, dermoscopic assessment, and potassium hydroxide microscopy. Sensitivity, specificity, positive predictive value, negative predictive value, and receiver operating characteristic analysis were calculated.

Results: Potassium hydroxide microscopy confirmed *pityriasis versicolor* in 62 of 113 participants (54.9%). Dermoscopy demonstrated 100% sensitivity and 100% negative predictive value, with specificity of 7.8% and positive predictive value of 56.9%. Wood's lamp showed sensitivity of 80.6%, specificity of 66.7%, positive predictive value of 74.6%, and negative predictive value of 66.7%. Receiver operating characteristic analysis revealed an area under the curve of 0.539 for dermoscopy and 0.737 for Wood's lamp.

Conclusion: Dermoscopy identified all potassium hydroxide-positive cases in this cohort and may serve as a useful screening tool in low-resource settings. Wood's lamp demonstrated higher specificity. Integrating dermoscopy with clinical assessment may enhance early diagnosis where microscopy is unavailable.

Keywords: *Pityriasis versicolor*; dermoscopy; Wood's lamp; potassium hydroxide microscopy; diagnostic accuracy; screening tools; resource limited settings; superficial fungal infections.

© 2026 Christabel A. Ovesuor, Uche Rowland Ojinmah, Gladys Ozoh, Kennedy Oberhiri Obowhewu, Celestine Emeka Ekwuluo, Kenechi Gerald Ike, Festus Ituah, Kingsley Chike Madubuike, Oluwapelumi Silvanus Ajayi, this work is licensed under a Creative Commons Attribution 4.0 International License (CC BY 4.0). The authors retain copyright and allow others to share, adapt, or redistribute the work with proper attribution.

Cite This Article: Ovesuor, C. A., Ojinmah, U. R., Ozoh, G., Obowhewu, K. O., Ekwuluo, C. E., Ike, K. G., ... Ajayi, O. S. (2026). Dermoscopy and Wood's Lamp Compared with Potassium Hydroxide Microscopy in *Pityriasis Versicolor*: A Cross-Sectional Diagnostic Accuracy. *The American Journal of Applied Sciences*, 8(04), 36–46. <https://doi.org/10.37547/tajas/Volume08Issue04-04>

1. INTRODUCTION

Pityriasis versicolor is recognised as a common superficial fungal infection caused by lipophilic yeasts of the genus *Malassezia*. Recent research has strengthened understanding of the organism's pathogenic behaviour, particularly its ability to shift from a commensal to a pathogenic state under favourable environmental conditions (Saunte et al., 2020). The condition typically manifests as hypo or hyperpigmented macules and patches that appear on seborrhoeic areas such as the trunk, neck, and proximal upper limbs. Although many individuals remain asymptomatic, visible pigmentary

alteration often leads to clinical consultation, especially in settings where cosmetic concerns influence health seeking behaviour (Leung et al., 2022).

Clinical diagnosis remains central to routine practice. Potassium hydroxide microscopy continues to serve as a reliable reference method, allowing direct visualisation of the characteristic mixture of spores and short hyphae that supports identification of *Malassezia* species (Hamdino et al., 2022; Li et al., 2022; Bailina et al., 2024). Wood's lamp examination is also used in many dermatology clinics, with yellow green or yellow orange fluorescence frequently reported in confirmed cases

(Dyer & Foy, 2022). These approaches remain valuable, yet they depend on equipment availability and practitioner experience, which can vary considerably across regions.

Dermoscopy has gained increasing attention as a non-invasive diagnostic tool that enhances visual assessment of superficial fungal infections. Its ability to reveal subsurface epidermal structures has been highlighted in recent dermatology research, which describes dermoscopic patterns such as diffuse scaling, altered pigment networks, and folliculocentric changes in confirmed cases of pityriasis versicolor (Errichetti, 2020). Studies conducted in diverse clinical settings, including South Asia and the Middle East, have reported consistent dermoscopic findings that support its potential role in improving diagnostic confidence (Lopez et al., 2019; Almeziny et al., 2025; Lim et al., 2026). These studies suggest that dermoscopy may offer a practical adjunct in environments where laboratory support is limited.

Despite these developments, evidence directly comparing dermoscopy with established diagnostic tools remains limited in Sub Saharan Africa. This gap is significant, as diagnostic accuracy research is particularly important in regions where access to microscopy or specialist dermatology services may be constrained. Strengthening diagnostic pathways for superficial fungal infections has broader implications for clinical management, public health planning, and resource allocation. The wider research from which this study emerges highlights the need for context specific evaluation of diagnostic tools that can be integrated into routine care without imposing additional burdens on already stretched health systems.

The present study addresses this gap by evaluating dermoscopy and Wood's lamp examination against potassium hydroxide microscopy as the reference standard within a defined clinical population. This approach allows a clearer understanding of the diagnostic value of each method and supports efforts to refine clinical pathways for the assessment of pityriasis versicolor in resource limited settings. The findings contribute to ongoing discussions about practical, accessible diagnostic strategies that can be implemented reliably across diverse healthcare environments.

2.METHODS

Study Design and Setting

This hospital based cross sectional diagnostic accuracy study was conducted in the dermatology clinic of a tertiary teaching hospital in South East Nigeria between April and October 2022. Cross sectional diagnostic accuracy designs are widely used in dermatology research to evaluate the performance of clinical and laboratory tools under routine conditions (Bossuyt et al., 2015; Carrera et al., 2018; Jakhar et al., 2021).

Participants

Adults aged 18 years and above who presented with clinical features consistent with pityriasis versicolor were consecutively recruited. Consecutive sampling is recommended in diagnostic accuracy studies to minimise selection bias and ensure that the study population reflects real world clinical presentations (Hall, Kea & Wang, 2019). Individuals were excluded if they had used topical antifungal agents within the preceding two weeks or systemic antifungal therapy within the preceding four weeks, as recent antifungal exposure may reduce fungal load and affect diagnostic test performance (Saunte et al., 2020).

Procedures

All participants underwent three diagnostic assessments. Wood's lamp examination was performed in a darkened room. Yellow orange fluorescence was considered a positive finding. Wood's lamp remains a recognised adjunctive tool in the assessment of superficial fungal infections, although its sensitivity varies across skin phototypes (Sato et al., 2020).

Dermoscopy was conducted using a smartphone attached dermoscope at $\times 200$ magnification. Dermoscopy has been increasingly applied in the evaluation of superficial fungal infections, with recognised features including non-uniform pigmentation, scaling patterns, vascular structures, and perifollicular or perilesional changes (Errichetti, 2020). The presence of any of these features was considered suggestive of pityriasis versicolor.

Potassium hydroxide microscopy was performed using 10% KOH with lactophenol cotton blue staining. Identification of spores and short hyphae constituted a positive result. KOH microscopy remains the reference standard for diagnosing pityriasis versicolor due to its direct visual confirmation of fungal elements (Łabędź et al., 2023).

Potassium hydroxide microscopy served as the reference standard for all diagnostic comparisons.

Statistical Analysis

Data were analysed using SPSS version 23. Sensitivity, specificity, positive predictive value, and negative predictive value were calculated in line with established diagnostic accuracy reporting standards (Bossuyt et al., 2015). Receiver operating characteristic curves were constructed, and area under the curve values were determined to assess overall diagnostic performance. Statistical significance was set at $p < 0.05$.

3. RESULTS

Participant Flow and Reference Standard Findings

A total of 120 patients met the eligibility criteria during the recruitment period. Seven declined participation, primarily due to reluctance to undergo skin scraping. One hundred and thirteen participants completed all diagnostic procedures and were included in the analysis (Figure 1).

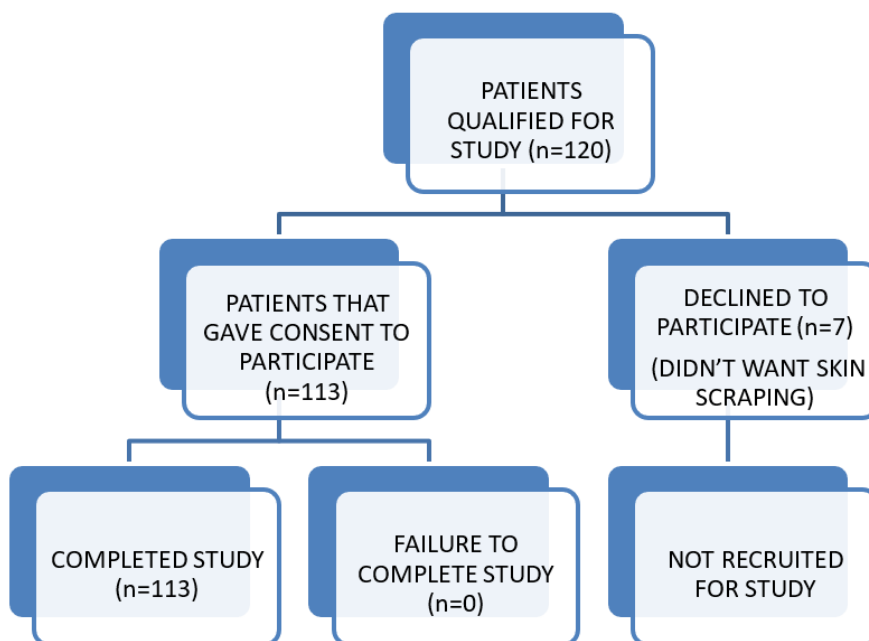


Figure 1: Flow diagram of participant recruitment and completion

Potassium hydroxide microscopy, used as the reference standard, confirmed pityriasis versicolor in 62 of 113 participants (54.9%). Fifty-one participants (45.1%) were negative on microscopy.

Diagnostic Performance of Dermoscopy

Dermoscopy identified 109 participants as positive and 4 as negative. All 62-potassium hydroxide-positive cases

were detected through dermoscopy. This yielded a sensitivity of 100% and a negative predictive value of 100%.

However, 47 of the 51-potassium hydroxides-negative cases were classified as positive by dermoscopy, resulting in a specificity of 7.8%. The positive predictive value was 56.9%.

Table 1: Dermoscopy Versus Potassium Hydroxide Microscopy

Dermoscopy	KOH Positive (n = 62)	KOH Negative (n = 51)	Total
Positive	62	47	109

Negative	0	4	4
Total	62	51	113

To allow clearer interpretation of diagnostic indices, summary performance measures are presented separa

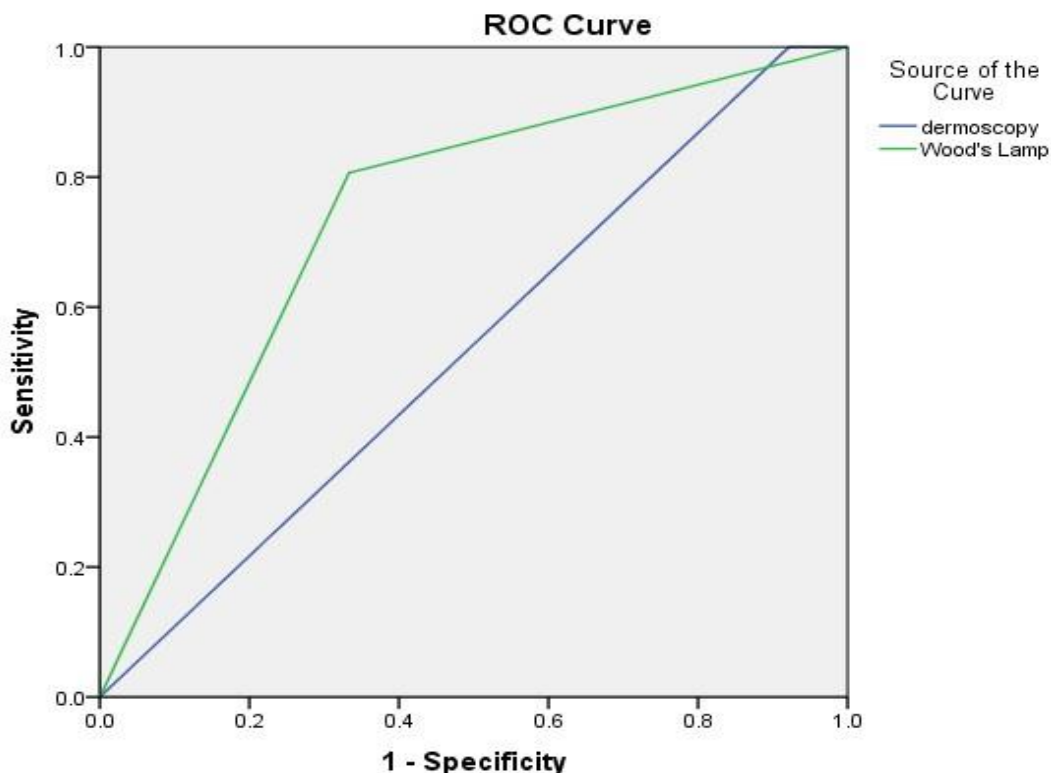
Table 2: Diagnostic Performance of Dermoscopy

Measure	Value
Sensitivity	100%
Specificity	7.8%
Positive Predictive Value	56.9%
Negative Predictive Value	100%

Receiver operating characteristic (ROC) analysis demonstrated an area under the curve of 0.539 (95% CI 0.431–0.647; p = 0.474), indicating limited discriminatory ability when potassium hydroxide is used as the comparator.

Table 3: ROC Analysis for Dermoscopy

	Area under curve	Standard error	95% CI	P value
Dermoscopy	0.539	0.055	0.431 – 0.647	0.474
Wood lamp	0.737	0.737	0.641 – 0.832	0.049



Diagonal segments are produced by ties.

Figure 2: ROC Curve for Dermoscopy

Diagnostic Performance of Wood’s Lamp

Wood’s lamp examination identified 67 participants as positive and 46 as negative. Of the 62-potassium hydroxide-positive cases, 50 were correctly identified, resulting in a sensitivity of 80.6%. Twelve cases were false negatives.

Among the 51-potassium hydroxide-negative cases, 34 were correctly classified, producing a specificity of 66.7%. The positive predictive value was 74.6%, and the negative predictive value was 66.7%.

Table 4: Wood’s Lamp Versus Potassium Hydroxide Microscopy

Wood’s Lamp	KOH Positive (n = 62)	KOH Negative (n = 51)	Total
Positive	50	17	67
Negative	12	34	46
Total	62	51	113

Summary performance indicators are presented below.

Table 5: Wood’s Lamp in the diagnosis of patients with pityriasis versicolor

	KOH		Sensitivity	Specificity	PPV	NPV
	Positive (n = 62)	Negative (n = 51)				
Wood’s Lamp						
Positive	50	17	80.6%	66.7%	74.6%	66.7%
Negative	12	34				

ROC analysis showed an area under the curve of 0.737 (95% CI 0.641–0.832; p = 0.049), indicating moderate discriminatory performance.

Table 6: ROC Analysis for Wood's Lamp

Statistic	Value
Area Under Curve	0.737
Standard Error	0.055
95% CI	0.641–0.832
p value	0.049

Comparative Diagnostic Performance

Direct comparison of diagnostic indices demonstrates that dermoscopy achieved higher sensitivity (100%) compared with Wood's lamp (80.6%). In contrast, Wood's lamp demonstrated markedly higher specificity (66.7%) than dermoscopy (7.8%).

Negative predictive value was highest for dermoscopy (100%), whereas Wood's lamp demonstrated higher positive predictive value (74.6%).

Table 7: Comparative summary of diagnostic performance of dermoscopy and Wood's lamp relative to potassium hydroxide microscopy.

Measure	Dermoscopy	Wood's Lamp
Sensitivity	100%	80.6%
Specificity	7.8%	66.7%
Positive Predictive Value	56.9%	74.6%
Negative Predictive Value	100%	66.7%
Area Under Curve	0.539	0.737

These findings establish distinct performance profiles for each modality within this clinical population

4. DISCUSSION

This study assessed dermoscopy and Wood's lamp examination against potassium hydroxide microscopy within a defined clinical cohort. Dermoscopy identified all microscopy confirmed cases, producing a sensitivity of 100%. The negative predictive value of 100% indicates that dermoscopy performed well in ruling out disease when characteristic features were absent. High sensitivity has been reported in recent dermoscopic research on superficial fungal infections, which highlights the value of dermoscopy as a rapid, non-invasive assessment tool in routine dermatology practice (Chauhan, Meena & Errichetti, 2023; Heckler et al., 2023; Alsaratee, 2025).

Specificity for dermoscopy was low at 7.8%, which requires careful interpretation. Potassium hydroxide microscopy, although widely regarded as a reference method, is not infallible. Operator experience, sampling technique, and fungal load can influence diagnostic yield. Studies examining the performance of KOH microscopy have noted that false negatives may occur when the sample is inadequate or when fungal elements are sparse (Velasquez-Agudelo & Cardona-Arias, 2017;

Khan et al., 2022). Research has also shown that the use of contrast stains can improve the visibility of fungal structures and enhance sensitivity (Hoffman et al., 2022). Low specificity in this study may therefore reflect limitations of the reference standard rather than poor dermoscopic performance.

Wood's lamp examination demonstrated higher specificity and positive predictive value than dermoscopy. Fluorescence under ultraviolet light remains a recognised adjunctive method for diagnosing pityriasis versicolor, although its performance varies across skin phototypes and disease stages (Errichetti et al., 2025). In this cohort, Wood's lamp sensitivity was lower, with 12 false negatives. Reduced sensitivity has been described in previous work, particularly in cases where fluorescence is subtle or absent due to low metabolite production by the organism (Leung et al., 2022).

Findings from this study align with recent research reporting high dermoscopic sensitivity in pityriasis versicolor. Dermoscopic studies conducted in different regions have consistently described characteristic patterns that support diagnosis, even when clinical

features are mild (Javed et al., 2020; Williams et al., 2021). Direct comparative studies between dermoscopy and Wood's lamp remain limited, although available evidence suggests that dermoscopy offers greater sensitivity, while Wood's lamp may provide better discrimination between affected and unaffected skin (Dyer & Foy, 2022). The present findings support this pattern, indicating that dermoscopy may function effectively as a screening tool, while Wood's lamp may help reduce false positives.

Clinical skill remains central to dermatological diagnosis. Dermoscopy should complement, rather than replace, clinical evaluation. In low resource settings where microscopy is unavailable, dermoscopy offers a practical, non-invasive option that can be integrated into routine care. The wider research from which this study emerges highlights the importance of strengthening diagnostic pathways for common skin conditions in environments where laboratory access is limited. The combined use of dermoscopy and Wood's lamp may offer a balanced approach, improving diagnostic confidence while reducing reliance on microscopy.

Strengths and Limitations

This study offers a clear examination of dermoscopy and Wood's lamp performance against potassium hydroxide microscopy within a defined clinical population. One strength lies in the use of consecutive recruitment, which ensured that the sample reflected the range of presentations seen in routine dermatology practice. The study also applied consistent procedures across all participants, which supported fair comparison between the diagnostic methods. Conducting the work in a real world clinical environment adds further value, as the findings reflect the conditions under which these tools are commonly used.

The study design allowed direct comparison between dermoscopy, Wood's lamp examination, and potassium hydroxide microscopy. This approach provided insight into how each method performs when applied to the same individuals, which strengthens the interpretation of relative diagnostic value. The inclusion of both non-invasive tools also reflects the practical realities of dermatological assessment in settings where laboratory support may be limited.

Several limitations should be acknowledged. The study was conducted in a single tertiary hospital, which may limit the extent to which the findings can be generalised

to other clinical environments, particularly primary care settings or regions with different patient demographics. The sample size, although adequate for exploratory analysis, may not capture the full spectrum of disease severity or atypical presentations. Operator experience may also have influenced the performance of each diagnostic method, as dermoscopy, Wood's lamp interpretation, and microscopy all require skill and familiarity.

Potassium hydroxide microscopy served as the reference standard, yet it is not without its own constraints. Sampling technique, fungal load, and slide preparation can affect the accuracy of microscopy, which may influence estimates of sensitivity and specificity for the other diagnostic tools. The study did not incorporate culture or molecular methods, which could have provided additional confirmation of fungal presence. Although these methods are not routinely available in many low resource settings, their absence limits the ability to assess the full diagnostic landscape.

Despite these limitations, the study contributes meaningful evidence on the comparative performance of dermoscopy and Wood's lamp examination in the assessment of pityriasis versicolor. The findings support the wider research aim of strengthening diagnostic pathways in environments where access to laboratory facilities may be constrained.

Implications for Practice

The findings from this study have several implications for clinical practice, particularly in environments where access to laboratory facilities is limited. Dermoscopy demonstrated excellent sensitivity and a strong ability to exclude disease when characteristic features were absent. This performance suggests that dermoscopy can support rapid assessment in routine dermatology clinics and may help clinicians make confident decisions when microscopy is unavailable. Its portability and ease of use make it especially valuable in primary care settings, outreach clinics, and other resource constrained environments.

Wood's lamp examination showed greater specificity, which indicates that it may assist clinicians in distinguishing non-cases more effectively. When used alongside dermoscopy, Wood's lamp may help reduce false positives and strengthen overall diagnostic confidence. The complementary strengths of both tools highlight the potential value of a combined approach,

particularly when clinicians must make decisions without immediate access to potassium hydroxide microscopy.

The study also reinforces the importance of clinical judgement. Neither dermoscopy nor Wood's lamp should be used in isolation, and both tools perform best when interpreted within the broader context of patient history and clinical examination. Training in dermoscopic interpretation may further enhance diagnostic accuracy, especially for clinicians working in settings where fungal infections are common.

For health systems, the findings point to the practical benefits of integrating low cost, non-invasive diagnostic tools into routine dermatology services. Wider availability of dermoscopes and Wood's lamps could support earlier diagnosis, reduce unnecessary treatment, and improve patient outcomes. These tools may also help streamline referral pathways by enabling frontline clinicians to make more informed decisions before seeking specialist input.

The results align with the wider research aim of strengthening diagnostic capacity in resource limited settings. Incorporating dermoscopy and Wood's lamp examination into standard practice may help reduce reliance on laboratory infrastructure and support more equitable access to dermatological care.

Future Research

Future research should explore the performance of dermoscopy and Wood's lamp examination across a wider range of clinical settings, including primary care centres and community-based clinics where access to microscopy is often limited. Larger, multi-site studies would help determine whether the diagnostic patterns observed in this study hold across different populations, skin phototypes, and levels of clinician experience. Such work would also support a clearer understanding of how these tools function when used by non-specialists, which is particularly relevant in regions where dermatology services are scarce.

Further investigation into the combined use of dermoscopy and Wood's lamp examination may offer additional insight into how these tools complement one another in practice. Studies designed to assess sequential or integrated diagnostic pathways could help identify the most efficient and reliable approach for frontline clinicians. Research that incorporates digital image analysis or teledermatology may also be valuable,

especially as mobile based diagnostic support becomes more accessible in low resource environments.

There is also scope for studies that examine the impact of training on diagnostic accuracy. Structured dermoscopy training programmes could be evaluated to determine how quickly clinicians acquire the skills needed to recognise key features of pityriasis versicolor. Understanding the relationship between training, experience, and diagnostic performance would help guide the development of practical educational interventions.

Future work may also consider the role of patient reported outcomes and the broader clinical impact of improved diagnostic accuracy. Exploring how rapid, non-invasive diagnostic tools influence treatment decisions, follow up patterns, and patient satisfaction would provide a more comprehensive picture of their value in routine care. Such research would align with the wider aim of strengthening dermatological services in environments where resources are limited and clinical demand is high.

5. CONCLUSION

Dermoscopy identified all potassium hydroxide confirmed cases of pityriasis versicolor in this hospital-based study and showed excellent sensitivity and negative predictive value. Wood's lamp examination demonstrated greater specificity, indicating that it may help distinguish non-cases more effectively. These findings suggest that dermoscopy has considerable value as a screening tool, particularly in settings where laboratory support is limited and rapid assessment is needed. Wood's lamp examination may offer additional reassurance when differentiating between affected and unaffected skin.

Clinical judgement remains central to dermatological diagnosis, and neither dermoscopy nor Wood's lamp should be viewed as a replacement for careful clinical assessment. In resource limited environments, the combination of dermoscopy and Wood's lamp may strengthen diagnostic confidence when microscopy is unavailable. The results from this study support the wider research aim of improving access to practical, non-invasive diagnostic tools that can be integrated into routine care without imposing additional demands on overstretched health systems.

AUTHOR CONTRIBUTION

All authors played a substantive role in shaping this study and developing the manuscript. C.A.O. conceptualised the work and designed the overall study framework. Data analysis, interpretation of data and validation of findings were carried out collaboratively, with each author contributing to the discussions that informed the final results. K.O.O. and C.E.E. prepared the initial manuscript draft, covering the introduction, methods, results and discussion. Co-authors strengthened the analysis, offered detailed revisions and enhanced the clarity and coherence of the final document. Every author reviewed the complete manuscript, approved the final version and accepted responsibility for the integrity of the work.

ETHICS

Ethical approval for this study was granted by the Research Ethics Committee of University of Nigeria Teaching Hospital (UNTH), Ituku-Ozalla, Enugu State, Nigeria.

CONFLICTS OF INTEREST

The authors declare no conflicts of interest.

FUNDING

This research did not receive any grant from funding agencies in the public, commercial, or not-for-profit sectors.

ACKNOWLEDGEMENT

The authors would like to acknowledge the management and technical staff of PENKUP Research Institute, Birmingham, United Kingdom for their excellent assistance and for providing manuscript writing/editorial support in accordance with Good Publication Practice (GPP3) guidelines.

REFERENCES

- Almeziny, A., Almutairi, R., Altamimi, A., Alshehri, K., Almehaideb, L., Shadid, A., & Al Mashali, M. (2025). The Prevalence of Dermoscopy Use Among Dermatology Residents in Riyadh, Saudi Arabia: Cross-Sectional Study. *JMIR dermatology*, 8, e63861.
- Alsarate, H. H. (2025). Diagnostic tools and methods for dermatological assessment. *British Journal of Nursing*, 34(10), 502-512.
- Bailina, G. E., Nesipbaeva, A. E., & Kukhar, E. V. (2024). Improvement of direct microscopy method for differential diagnosis of skin mycoses. *Herald of Science of S Seifullin Kazakh Agro Technical Research University: Veterinary sciences*, 3 (007), 45-60.
- Bossuyt, P. M., Reitsma, J. B., Bruns, D. E., Gatsonis, C. A., Glasziou, P. P., Irwig, L., Lijmer, J. G., Moher, D., Rennie, D., de Vet, H. C. W., & Korevaar, D. A. (2015). STARD 2015: An updated list of essential items for reporting diagnostic accuracy studies. *BMJ*, 351, h5527. <https://doi.org/10.1136/bmj.h5527>
- Carrera, C., Segura, S., Aguilera, P., Takigami, C. M., Gomes, A., Barreiro, A., ... & Zalaudek, I. (2018). Dermoscopy improves the diagnostic accuracy of melanomas clinically resembling seborrheic keratosis: cross-sectional study of the ability to detect seborrheic keratosis-like melanomas by a group of dermatologists with varying degrees of experience. *Dermatology*, 233(6), 471-479.
- Chauhan, P., Meena, D., & Errichetti, E. (2023). Dermoscopy of bacterial, viral, and fungal skin infections: a systematic review of the literature. *Dermatology and Therapy*, 13(1), 51-76.
- Dyer, J. M., & Foy, V. M. (2022). Revealing the unseen: a review of Wood's lamp in dermatology. *The Journal of clinical and aesthetic dermatology*, 15(6), 25.
- Errichetti, E., (2020) Dermoscopy in Monitoring and Predicting Therapeutic Response in General Dermatology (Non-Tumoral Dermatoses): An Up-To-Date Overview. *Dermatol Ther (Heidelb)*. 2020 Dec;10(6):1199-1214. doi: 10.1007/s13555-020-00455-y. Epub 2020 Oct 8. Herrich
- Errichetti, E., Pietkiewicz, P., Bhat, Y. J., Salwowska, N., Szlązak, P., & Stinco, G. (2025). Diagnostic accuracy of ultraviolet-induced fluorescence dermoscopy in non-neoplastic dermatoses (general dermatology): A multicentric retrospective comparative study. *Journal of the European Academy of Dermatology and Venereology*, 39(1), 97-108.
- Hall, M. K., Kea, B., & Wang, R. (2019). Recognising bias in studies of diagnostic tests part 1: patient selection. *Emergency Medicine Journal*, 36(7), 431-434.
- Hamdino, M., Saady, A. A., El-Shahed, L. H., & Taha, M. (2022). Identification of Malassezia species isolated from some Malassezia associated

- skin diseases. *Journal of Medical Mycology*, 32(4), 101301.
12. Heckler, I., Sabalza, M., Bojmehrani, A., Venkataraman, I., & Thompson, C. (2023). The need for fast and accurate detection of dermatomycosis. *Medical Mycology*, 61(5), myad037.
 13. Hoffman, J. J., Yadav, R., Sanyam, S. D., Chaudhary, P., Roshan, A., Singh, S. K., ... & Burton, M. J. (2022). Diagnosis of fungal keratitis in low-income countries: evaluation of smear microscopy, culture, and in vivo confocal microscopy in Nepal. *Journal of Fungi*, 8(9), 955.
 14. Jakhar, D., Kaul, S., Kaur, I., Kumar, S., (2021) Wifi-enabled dermoscopy: what is the potential in clinical practice and education?, *Clinical and Experimental Dermatology*, Volume 46, Issue 7, 1 October 2021, Pages 1317–1319, <https://doi.org/10.1111/ced.14692>
 15. Javed, R., Rahim, M. S. M., Saba, T., & Rehman, A. (2020). A comparative study of features selection for skin lesion detection from dermoscopic images. *Network Modeling Analysis in Health Informatics and Bioinformatics*, 9(1), 4.
 16. Khan, S., Farabi, B., Navarrete-Dechent, C., Rao, B., & Safai, B. (2022). Applications of Reflectance Confocal Microscopy in the Diagnosis of Fungal Infections: A Systematic Review. *J. Fungi* 2023, 9, 39.
 17. Łabędź, N., Navarrete-Dechent, C., Kubisiak-Rzeczyk, H., Bowszyc-Dmochowska, M., Pogorzelska-Antkowiak, A., & Pietkiewicz, P. (2023). Pityriasis versicolor—a narrative review on the diagnosis and management. *Life*, 13(10), 2097.
 18. Leung, A. K. C., Barankin, B., & Hon, K. L. (2022). Pityriasis versicolor: An updated review. *Drugs in Context*, 11, 1–12. <https://doi.org/10.7573/dic.2022.3.7> (doi.org in Bing)
 19. Leung, A. K., Barankin, B., Lam, J. M., Leong, K. F., & Hon, K. L. (2022). Tinea versicolor: an updated review. *Drugs in context*, 11.
 20. Li, J., Feng, Y., Liu, C., Yang, Z., de Hoog, S., Qu, Y., ... & Shi, D. (2022). Presence of *Malassezia* hyphae is correlated with pathogenesis of seborrheic dermatitis. *Microbiology Spectrum*, 10(1), e01169-21.
 21. Lim, H. W., Zhang, C., Taylor, M., Dlova, N. C., Conceição, K., Jablonski, N., ... & Alexis, A. (2026). International expert consensus on knowledge gaps in care for dermatologic disorders in skin of color. *International Journal of Dermatology*, 65(1), 41-56.
 22. Lopez Carrera, Y. I., Al Hammadi, A., Huang, Y. H., Llamado, L. J., Mahgoub, E., & Tallman, A. M. (2019). Epidemiology, diagnosis, and treatment of atopic dermatitis in the developing countries of Asia, Africa, Latin America, and the Middle East: a review. *Dermatology and therapy*, 9(4), 685-705.
 23. Sato, T., Asahina, Y., Toshima, S., Yaguchi, T., & Yamazaki, K. (2020). Usefulness of Wood's lamp for the diagnosis and treatment follow-up of onychomycosis. *Medical Mycology Journal*, 61(2), 17-21.
 24. Saunte, D. M., Gaitanis, G., & Hay, R. J. (2020). *Malassezia*-associated skin diseases, the use of diagnostics and treatment. *Frontiers in cellular and infection microbiology*, 10, 112. <https://doi.org/10.3389/fcimb.2020.00112>
 25. Velasquez-Agudelo, V., & Cardona-Arias, J. A. (2017). Meta-analysis of the utility of culture, biopsy, and direct KOH examination for the diagnosis of onychomycosis. *BMC infectious diseases*, 17(1), 166.
 26. Williams, N. M., Rojas, K. D., Reynolds, J. M., Kwon, D., Shum-Tien, J., & Jaimes, N. (2021). Assessment of diagnostic accuracy of dermoscopic structures and patterns used in melanoma detection: a systematic review and meta-analysis. *JAMA dermatology*, 157(9), 1078-1088.